

AIRWAY MANAGEMENT IN THE RABBIT



Molly Varga, BVetMed, Dip. ZooMed (Mammalian), MRCVS

Abstract

A key factor when establishing a general anaesthetic protocol is proper airway management. Owing to its unique anatomy, the rabbit presents the anesthetist with several challenges regarding airway management. Methods for managing a rabbit patient's airway, along with the potential advantages and complications associated with these described techniques, is the focus of this clinical review. Copyright 2017 Elsevier Inc. All rights reserved.

Key words: rabbit; intubation; airway; supraglottic device; V-gel; nasotracheal intubation

Airway management is required during sedation and anesthesia to maintain a patent airway for oxygen delivery to the lungs and to facilitate ventilation of carbon dioxide. In critical cases, airway management may be necessary to enable cardiopulmonary resuscitation and ventilation.

Laryngeal and tracheal trauma have both been reported in rabbits following or attempting endotracheal intubation.^{1,2} The adverse complications associated with rabbit intubation are likely to increase for health care providers who are inexperienced with this procedure. The risk associated with intubation should be considered as part of a balanced airway management protocol, therefore alternative options should be available including injectable anesthesia, masks, nasal intubation, or a supraglottic airway device. Appropriate airway management includes protection of the airway from desiccation, irritation, and excess discharges.

ANATOMY

There are several anatomic issues that make airway management a challenge in the rabbit. The open mouth does not allow for clear visualisation of the glottis. Identifying the rabbit glottis without additional instrumentation, in most cases, is not possible. The oral cavity is long and narrow while the fleshy base of the tongue (or "torus") fills the back of the throat, further impeding visualisation.

As near obligate nasal breathers, the rabbit's glottis should normally be engaged with the soft palate; consequently, in normal circumstances, the soft-palate will have to be "flipped" off of the epiglottis to visualize this anatomic structure. The diameter of the rabbit trachea is less than would be predicted, based on the animal's size and weight, and the trachea is comprised of complete cartilage rings.

METHODS OF ENDOTRACHEAL INTUBATION

Endotracheal intubation is commonly employed as part of a general anaesthetic protocol to facilitate the delivery of inhaled anaesthetics to the lungs. Endotracheal intubation in rabbits is made more difficult by the anatomic constraints described above. There are 3 ways of achieving endotracheal intubation in rabbit patients.

Blind Method

The blind method can be defined as the introduction of an endotracheal tube through the mouth without visualisation of the glottis. Before

From the Manor Vets, Birmingham, UK.

Address correspondence to: Molly Varga, BVetMed DZooMed MRCVS RCVS, Rutland House Veterinary Referrals Exotics Service, St Helens, Merseyside, UK. E-mail: mollyv@manorvets.com

© 2017 Elsevier Inc. All rights reserved.

1557-5063/17/2101-\$30.00

<http://dx.doi.org/10.1053/j.jepm.2016.10.014>

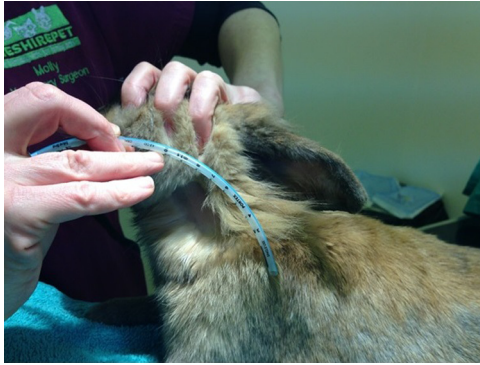

FIGURE 1. Measuring the endotracheal tube before insertion.

sedating the rabbit, premeasuring the endotracheal tube length on the outside of the rabbit is required to ensure proper length and placement depth (Fig. 1). The patient should first be induced to a suitable level of sedation or immobility. Intubation should never be attempted in a rabbit that is still able to voluntarily or reactively move its jaws. Once induced, the rabbit should be placed in sternal recumbency with the neck extended in a cranial/dorsal position (but not to the extent that the neck is vertical). The lubricated endotracheal tube (2 to 2.5 mm for a 2 to 4 kg rabbit) is inserted into the mouth and directed past the torus into the pharynx. It is not necessary to use a mouth gag. Local anesthetic can be sprayed onto the glottis or applied directly on the tube.

Breath sounds from the rabbit are used to determine the location of the endotracheal tube tip. The endotracheal tube is gently advanced until either the tip contacts the glottis or the breath sounds are lost, indicating the tube tip has passed the glottis opening. The tube is then slightly withdrawn until breath sounds are regained; after which it is gently advanced again into the glottis opening (Fig. 2).

The rabbit often coughs as the tube enters the trachea, and placement can be confirmed by listening for breath sounds (which should still be present), observation of the reservoir bag synchronized with respiratory effort, or capnography (Fig 3).

The pros of the blind intubation method are that once one becomes experienced with the procedure it is easy and quick to perform and requires little additional equipment.

The cons of this method are that until experience is gained, it is technically difficult. Moreover, without due diligence, it is possible to damage the delicate tissues of the glottis and risk laryngospasm. As the soft palate usually lies over

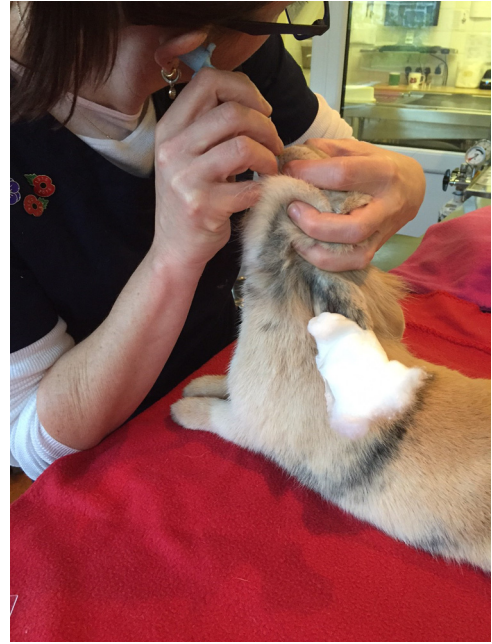


FIGURE 2. Blind technique for endotracheal tube insertion.

the glottis, visualization and application of local anaesthetic to this structure is difficult. Under normal circumstances, many rabbits have food in the pharynx; therefore, it is possible that this material could be pushed into the trachea when performing the blind intubation technique.

Endoscopic

Before sedating the rabbit, premeasuring the endotracheal tube length on the outside of the rabbit is required to ensure proper length and placement depth. The patient should first be induced to a suitable level of sedation or immobility. Intubation should never be attempted in a rabbit that is still able to voluntarily or reactively move its jaws. Once induced, the rabbit should be placed in sternal recumbency with the

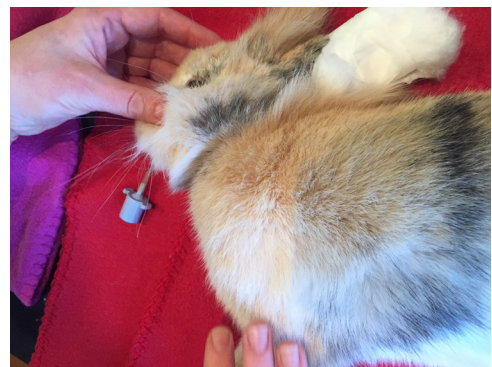


FIGURE 3. Endotracheal tube in situ.

neck extended in a cranial/dorsal position (but not to the extent that the neck is vertical). A mouth gag is placed so that the endoscope is protected from potential damage.

Two methods can be used for endoscopic intubation in rabbits: (1) to simply visualise the glottis with the lubricated endotracheal tube being passed into the glottis independently under visual control, and (2) the endoscope can be passed through the center of the tube and used as a direct guide and stylus for the tube. A local anesthetic agent can be sprayed onto the glottis or applied directly to the tube.

The pros of this method are that direct visualisation of the glottis allows for accurate and rapid intubation with minimum potential for soft tissue damage, any food left in the pharynx can be visualised and removed before intubation, and the technique is quick to learn and technically easy.

The cons of this method include the necessity for expensive equipment, risk of damage to the equipment should the rabbit move or react, and the size of the rabbit patient and tube that may limit the possibility of using the endoscope as a "stylus" (this is only possible in larger animals where the endoscope can fit through the endotracheal tube and is long enough to protrude from the end).

Laryngoscope (or Otoscope)

Before sedating the rabbit, premeasuring the endotracheal tube length on the outside of the rabbit is required to ensure proper length and placement depth. The patient should first be induced to a suitable level of sedation or immobility. Intubation should never be attempted in a rabbit that is still able to voluntarily or reactively move its jaws. Once induced, the rabbit should be placed in sternal recumbency with the neck extended in a cranial/dorsal position (but not

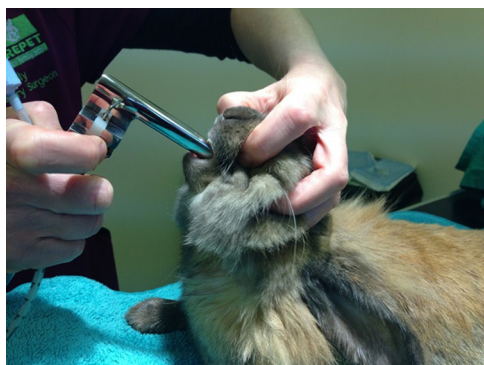


FIGURE 4. Using a laryngoscope to visualize the glottis.

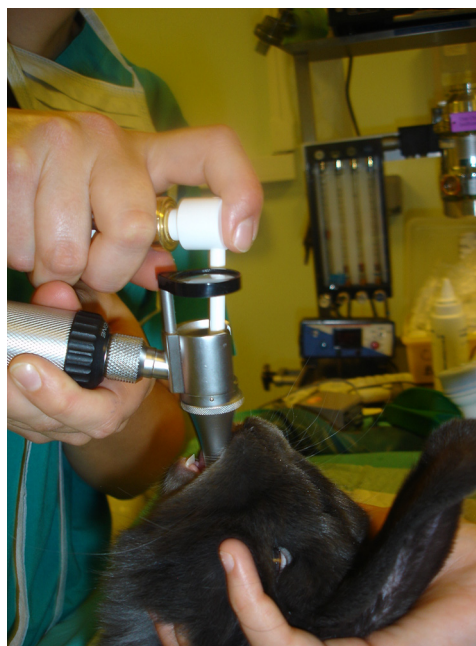

FIGURE 5. Local anesthetic spray is applied via the otoscope (or laryngoscope) and then the animal is oxygenated for 60 seconds before intubation.

to the extent that the neck is vertical). The laryngoscope (or otoscope) is introduced through the side of the patient's mouth and is positioned so that the soft palate is elevated dorsally to expose the glottis (Fig. 4). At this point it is easy to apply a local anaesthetic agent to the glottis under direct visualisation (Fig. 5). The endotracheal tube can then be passed along the laryngoscope blade with the tube tip being introduced into the trachea.

There are 2 methods one can use to intubate a rabbit with an otoscope: (1) use the otoscope to visualize the glottis as described above and visually guide the endotracheal tube into the trachea, and (2) the otoscope can be used as a guide for a stylet, which is visually positioned in the trachea and the otoscope removed; this allows for the tube to be

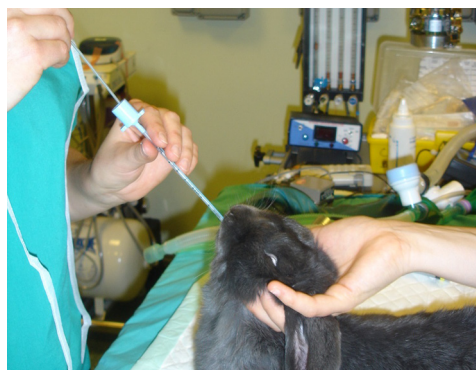

FIGURE 6. If a stylet is used, once it has been placed, the tube is simply slid down into the glottis.

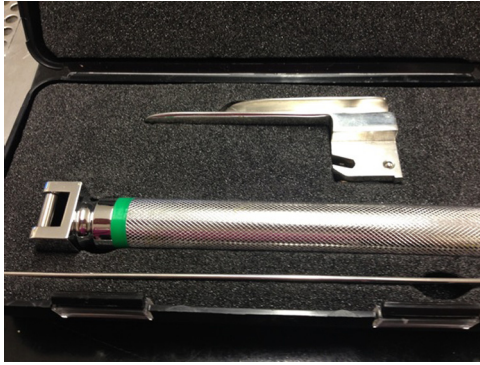


FIGURE 7. A Flecknell laryngoscope.

threaded into the trachea over the stylet, which is then removed (Fig. 6).

The pros of the laryngoscope (or otoscope) method are that it is technically easy, there is minimal risk of soft tissue damage, successful intubation and application of a local anaesthetic agent to the glottis are visually confirmed, and should food be present in the pharynx, it can be removed before entry into the trachea. The equipment is relatively inexpensive and widely available. Using a stylet is recommended when learning the laryngoscope (or otoscope) technique.

The cons of this method are minimal; the requirement for a specialized laryngoscope blade is one consideration (Fig. 7).

SUPRAGLOTTIC AIRWAY DEVICES

Supraglottic airway devices (SAD) are widely used in human anesthesia for both routine and emergency airway management.³ Supraglottic airway devices are a means of providing oxygen and gaseous anaesthesia without entering the trachea. These devices form a seal on the ventral surface of the pharynx, around the larynx, and allow ventilation without intubating through the larynx and into the trachea. This reduces the risk of upper airway trauma, makes insertion of the airway device easier and rapid, and improves patient comfort on recovery. Supraglottic airway devices are especially useful for the management of difficult airways in emergency situations as they do not require the same degree of visualization of the glottis as endotracheal intubation. A variety of human SAD are commercially available, ranging from devices that have an inflatable section to form a pharyngeal seal (laryngeal mask airway) to those relying on a soft compressible material and an anatomically mirrored design (i-gel) to achieve the same seal. The SAD can be used during both spontaneous respiration and positive pressure

ventilation. A variety of human SAD has been used in rabbits with varying degrees of success.^{4,5} Most complications associated with the veterinary use of human SAD appear to stem from the large variation in upper airway anatomy between rabbits and humans.

The V-gel system (Fig. 8), which has SAD designed especially for rabbits, is manufactured with a specially shaped end that is inserted into the pharynx and lodges over the glottis. The V-gel masks are made of soft plastic, which when lubricated cause very little friction, and are designed to fit snugly over the opening to the trachea providing a sufficient seal to prevent aspiration of stomach contents and to allow IPPV.⁶ The primary advantage of the V-gel system is the ease of insertion and use. Although the manufacturers recommend that capnography be used to confirm placement, this can also be achieved by feeling the breath at the end of the tube, especially in larger individuals. Placement of a supraglottic device should not be attempted in any rabbit that can voluntarily or reactively move its jaws.

Protocol for insertion of a V-gel SAD is as follows:

- Appropriate size device is selected and lubricated.
- Rabbit is placed in sternal recumbency.
- Oral cavity is checked for food or cecotrophs and, if present, removed.
- Operator grasps and extends the tongue out of the mouth and to one side.

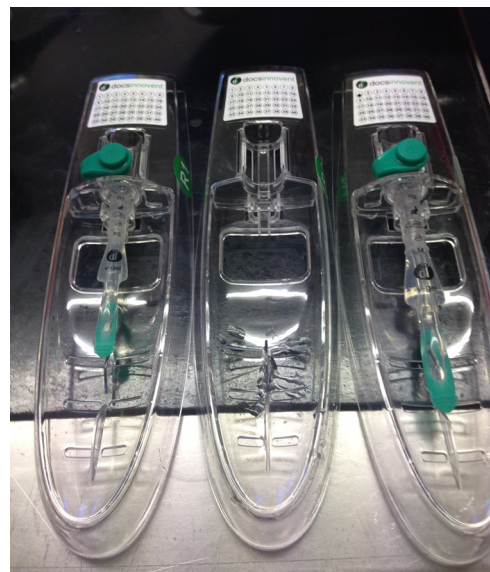


FIGURE 8. Supraglottic airway devices (V-gels).

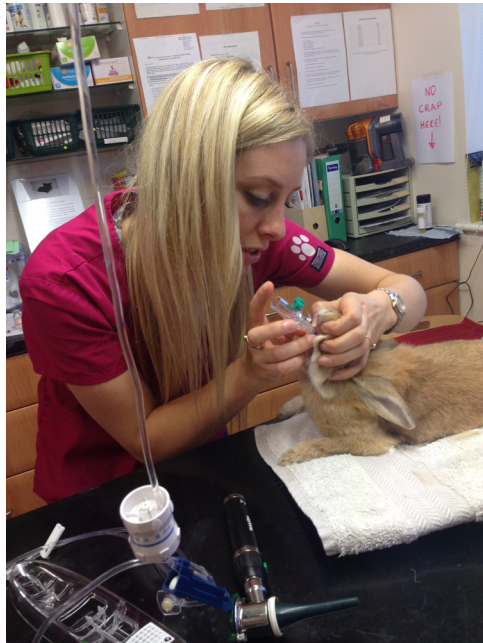

FIGURE 9. Insertion of a supraglottic airway device.

- Supraglottic device is then inserted directly into the mouth (Fig. 9)
- Baffle plate at the end of the device should sit snugly between the upper and lower incisors (Fig. 10).
- Capnograph confirms placement (Fig. 11).
- Rabbit tongue may occasionally appear cyanosed particularly when one achieves a very snug fit with the device. This is because of blood flow occlusion to the tongue and may not indicate true cyanosis. Use of the capnography and possibly a pulse oximeter placed on an alternative location (not the tongue) can confirm adequate cardiovascular function.
- Monitoring the V-gel SAD positioning during the procedure is important, especially if the

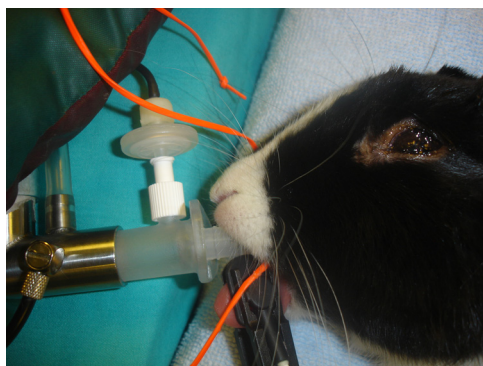


FIGURE 10. The baffle plate at the end of the supraglottic airway device fitting snugly between the upper and lower incisors.

animal is moved while under anesthesia. Use of capnography confirms correct placement.

The pros of this method are the speed and technical ease of device insertion.

The cons of this method are the fact that capnography, while not essential, is certainly very useful, the devices can be relatively easily dislodged if the patient is moved during the anesthetic event, and tongue cyanosis can occur. Positive pressure ventilation can lead to gastric tympani if the device is dislodged.

Nasal Intubation

Nasal intubation takes advantage of the fact that rabbits are obligate nasal breathers. Anesthesia can be maintained using a nasotracheal tube.⁷ Passing a tube through the nasal passages into the nasopharynx *theoretically* leads to direct access to the trachea. Anesthesia is induced to a suitable level; it is not appropriate to attempt nasal intubation in an animal that is able to voluntarily or reactively move.

The rabbit is placed either into sternal or dorsal recumbency. The neck is extended into dorsoflexion with the head pointing upward, suspending the body if in sternal recumbency, or the head is lifted while the back remains on the surface if in dorsal recumbency. A lubricated 2- to 2.5-mm soft (flexible) tube (approximately 15 cm in a 2- to 2.5-kg rabbit) is inserted into the external naris and directed ventromedially. A local anesthetic agent can be applied to the tube or directly into the nares. If resistance to insertion is felt, then the tube should be pulled back slightly and redirected. The rabbit often coughs once the tube enters the trachea. Placement is confirmed by visualization of condensation on the inside of the tube, visualization of the reservoir bag synchronized with the patient's breathing, or the use of capnography. The tube can then be used in the same manner as an orally placed endotracheal tube.

An alternative to this method is a nasal tube that is positioned to lie in the nasal passages. Small soft nasogastric tubes or 1.0- to 1.5-mm endotracheal tubes (Cook Veterinary Products) are suitable for nasal placement. The technique requires high flow rates to create positive pressure and force the anesthetic gases into the nasopharynx to be effective. Nasal intubation is useful in small rabbits that are difficult to intubate through the larynx. It may not be possible to pass a nasal tube

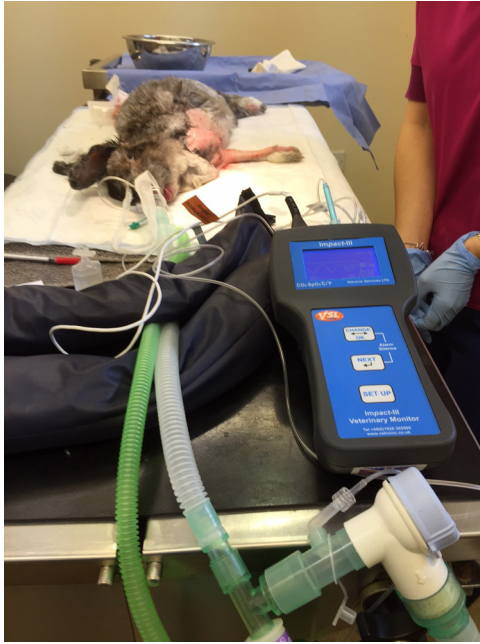

FIGURE 11. Supraglottic airway device in place with capnograph in use.

in a rabbit if the incisor tooth roots have penetrated the nasal passages.

Nasal intubation carries a risk of introducing pathogens, such as *Pasteurella multocida*, directly from the nasal cavity into the trachea and subsequently the lung.

TRACHEOSTOMY

This is an advanced technique that is indicated in emergency situations (tracheal obstruction) or where extensive access to the head/oral cavity is required, precluding intraoral intubation. A surgical plane of anaesthesia is essential to perform a tracheostomy. The rabbit should be placed in dorsal recumbency and the ventral neck clipped and aseptically prepared for surgical access. An incision should be made in the ventral midline of the neck aboral to the larynx. The trachea is identified and an incision made laterally between tracheal rings. An endotracheal tube is then inserted through the incision into the trachea.

Once the need for the tracheostomy is resolved, then surgical repair is required for proper healing of the incision site. Small gauge monofilament absorbable suture material is used to close the surgical defect. The sutures are placed around adjacent tracheal rings to close the tracheal incision, with minimal intrusion into the tracheal lumen.

The pros of this method are that it can be life-saving in emergency situations.

The cons of this method are that it is an invasive surgical procedure and should not be considered without the availability of suitable monitoring; there is also a risk of postsurgical tracheal stricture leading to dyspnea.

MEDICAL THERAPIES

Humidification

Airways that are artificially maintained (e.g., tracheotomies), and to an extent those that are intubated, have a reduced capacity to function in terms of humidifying and warming gases that contact lung tissue. Consequently, patients are predisposed to hypothermia, a reduction in ciliary function, and desiccation of respiratory secretions. All of these factors can contribute to a reduction in the protective capacity of the upper respiratory tract, contribute to increased likelihood of infection in the lower respiratory tract, and increase the morbidity and mortality of anaesthetised patients. Heated humidification devices can be inserted into the respiratory arm of the anaesthetic delivery system, and research suggests that the combination of warmth and humidity is better than humidification alone.⁸ The disadvantage of these devices is that they are often expensive and also increase the dead space within the circuit, a significant factor with smaller patients. Humidifiers are increasingly being used in veterinary situations; however, their use is not yet considered routine.

CONCLUSIONS

Poor standards of intubation technique, nonpliable endotracheal tubes (from repeated disinfection/use) (Fig. 12), lack of appropriate



FIGURE 12. New (above) and old (below) endotracheal tubes: illustrating the damage caused by repeated use.

lubrication, and inadequate monitoring or airway management during an anesthetic event are responsible for a high percentage of the problems associated with rabbit anesthesia. Veterinary clinicians should consider airway management in a holistic manner, considering all options available for the rabbit patient, without assuming the placement of an endotracheal tube is the only choice or even the “Gold standard” for care in every case.

REFERENCES

1. Phaneuf LR, Barker S, Groleau MA, et al: Tracheal injury after endotracheal intubation and anaesthesia in rabbits. *J Am Assoc Lab Anim Sci* 45:67-72, 2006
2. Grint NJ, Sayers IR, Cech R, et al: Postanaesthetic tracheal strictures in three rabbits. *Lab Anim* 40:301-308, 2006
3. Cook T, Howes B: Supraglottic airway devices: Recent advances. *Contin Educ Anaesth Crit Care Pain* 11: 56-61, 2011
4. Cruz M, Sacchi T, Luna S, et al: Use of a laryngeal mask for airway maintenance during inhalation anaesthesia in rabbits. *Vet Anesth Anal* 27:112-116, 2000
5. Bateman L, Ludders JW, Glead RD, et al: Comparison between facemask and laryngeal mask airway in rabbits during isoflurane anaesthesia. *Assoc Vet Anesth* 32: 280-288, 2005
6. Crotaz I: Initial feasibility investigation of the V-gel airway: An anatomically designed supraglottic airway device for use in companion animal veterinary anaesthesia. *Vet Anesth Anal* 37:579-580, 2010
7. Stephens De Valle JM: Successful management of rabbit anaesthesia through the use of nasotracheal intubation. *J Am Assoc Lab Anim Sci* 48(2):166-170, 2009
8. Raffe MR, Martin FB: Effect of inspired air heat and humidification on anaesthetic induced hypothermia in dogs. *Am J Vet Res* 44(3):455-458, 1983